

Contents:

- ⊕ Reflection
- ⊕ Delayed Splenic Rupture
- ⊕ Airway Care
- ⊕ Case of the month
- ⊕ Crossword
- ⊕ Letter to the Editor
- ⊕ Meetings

TRAUMA

Grapevine



Reflection

Recently Australia lost of one of its greatest advocates for optimal trauma care, Maria Seger, who died unexpectedly at her home on 27th August. Maria was Trauma Co-ordinator at Liverpool Hospital for 13 years and achieved much and was recognised as a world leader in clinical trauma nursing. She was a great advocate for the patient, always encouraging the team to improve patient care and was instrumental in developing performance indicators in trauma, quality in trauma care and data collection. Maria was a great educator of ALL personnel involved in care, especially nursing staff, registrars and ambulance officers.

She was a member of the Trauma Research Network Committee and represented this committee on the Trauma Systems Advisory Group of the Department of Health and was involved with the recent pilot Trauma Service Verification programme. She was a founding convenor of SWAN, was on the faculty of DSTC and co-ordinated the EMST courses at Liverpool Hospital.

Since Maria's death tributes to her have poured in from not just around Australia but from all over the world. She has left a huge legacy and was a great role model for nursing, achieving so much with so much compassion. Maria's death has been a huge loss to her husband Peter and family and all at Liverpool Hospital.

Maria will be remembered formally by the launch of the Maria Seger Trauma Nursing Scholarship. It is also my pleasure to include in this issue an article which she wrote in July of this year on the nurse's role in the trauma team.

Nurses have been the corner stone, the foundation for many aspects of trauma care and of course our trauma teams. Why is this? Their experience, constancy and practical approach delivered in a caring way is an inspiration, an inspiration shown best by Maria. We all miss her dearly.



Delayed Rupture of the Spleen: incidence, mechanisms and management

Helen Melsom, Trauma Student, University of Newcastle-upon-Tyne, UK.
Michael Sugrue Trauma Liverpool

INTRODUCTION

Delayed rupture of the spleen was first described by Baudet in 1902.¹ He suggested that the period of time from the injury to the splenic rupture was 48 hours or more and is characterized by a period of clinical quiescence, now referred to as "the latent period of Baudet".² Non-operative management of splenic injury has increased following recognition of the benefits of splenic preservation, in particular the prevention of post-splenectomy sepsis. Delayed splenic rupture is a complication of the non-operative management of splenic trauma.³ The discussion of delayed splenic rupture is complicated by confusion surrounding the definition. Until CT scanning became readily available, reported incidences were between 5 and 40%.⁴ Using new diagnostic techniques in the 1970s, the incidence was re-evaluated and considered

to be around 1%.⁵ This took into account cases which represented delayed diagnosis of splenic injury.

The importance of delayed rupture of the spleen lies in the relatively high mortality rates (5-15%), this is compared to the 1% mortality associated with acute splenic injury.²

MECHANISMS

There are a number of potential mechanisms for delayed splenic rupture. Baudet postulated that the bleeding appeared several days after injury due to an expanding subcapsular haematoma, which increased in size until it caused rupture of the splenic capsule. Alternatively, there was initial bleeding from a splenic laceration that ceased spontaneously, but began again days or weeks later when the



Delayed Rupture of the Spleen

Continued

perisplenic haematoma became dislodged. More recent case reports support the first mechanism.², Kluger et al. conclude that delayed splenic rupture represents a rupture of a subcapsular haematoma, which resulted from parenchymal injury.

Splenic pseudocysts are uncommon and usually result from blunt abdominal trauma. They form by the organisation of an intrasplenic haematoma. The blood is partially or completely absorbed leaving a brownish-green fluid surrounded by a fibrous capsule. The natural history of a post-traumatic pseudocyst is not clear. It has been estimated that around 25% will go on to rupture. An asymptomatic cyst, which develops following abdominal trauma and ruptures, possibly years later, is a potential mechanism for delayed splenic rupture.

Pseudoaneurysm formation of intraparenchymal splenic artery branches is a rare (but increasingly recognised) complication of traumatic splenic injury. Sugg et al. describe blunt abdominal trauma with progression of the pseudoaneurysm over time, demonstrated by the lack of evidence of it on the admission CT scan¹¹. Rupture of a pseudoaneurysm is another mechanism for delayed rupture of the spleen. Hiraide et al. documented a case of rupture from a pseudoaneurysm 7 days post injury.⁴ Considering the natural history of pseudoaneurysms in general it is possible for haemorrhage to occur days, months or even years after the initial injury. Evidence of a vascular blush should prompt either early embolization or surgery as these patient will usually continue to bleed.

MANAGEMENT

Splenectomy immediately after diagnosis has been the standard treatment for delayed splenic rupture.⁶ More conservative surgical procedures with splenic preservation are gaining wider acceptance in selected populations. In the case described by Hiraide et al. the patient was successfully treated with splenorrhaphy.⁴ Simple observation was the treatment for one patient in the review of cases by Farhat et al.⁶ Splenorrhaphy is often very difficult in patients with failed non-operative management.

Angiographic embolization is another method of management for haemorrhage caused by the rupture of a pseudoaneurysm in an otherwise haemodynamically stable patient.^{4,9}

Repeated imaging during the latent period may be helpful in detecting delayed splenic rupture in the patients at risk. However, indications for which patients are at risk are yet to be defined. Serial CT scanning is not routinely recommended. Farhat et al.⁶ found no period of specific symptoms and the onset of symptoms was often so sudden that they feel they occurred at the moment of rupture.

Evidence of an expanding haematoma on CT scan may be a predictor for impending rupture and an indication for surgery, but there is little data to support this hypothesis. Black et al.⁷ in 1992 concluded that the presence of a subcapsular haematoma did not predict delayed rupture.

PSEUDOCYSTS

The management of splenic pseudocysts needs also to be considered. The prevalence of such cysts seems to be rising, but this may be related to increasing use of CT imaging for upper abdominal discomfort.⁸ Pachter et al. reported a 3-year experience in 7 consecutive patients with traumatic cysts of the spleen. The authors conclude that small (less than 5 cm in diameter), asymptomatic cysts stand a reasonable chance of spontaneous resolution, which may take up to 3 years. However, cysts greater than 5 cm in diameter seem to be prone to the complications of rupture and infection and therefore require some form of interventional therapy. Options for treatment include percutaneous aspiration and transcatheter drainage, and if this fails (10%) cystectomy and splenectomy/splenorrhaphy will be required. It is important not to miss patients who continue to bleed after admission. This subgroup of patients eventually reach a critical point where they crash physiologically and become hypotensive. They are really not delayed rupture, rather patients with continued unrecognised persistent bleeding.


CONCLUSION

Delayed splenic rupture occurs in about 5-10% of patients managed non-operatively. It is an important clinical entity, which carries a mortality of 5-15%. Immediate laparotomy and splenectomy is preferable. More liberal controlled use of angiographic embolization may reduce the prevalence further.

References:

1. Schwartz, Shires and Spencer. Principles of Surgery. 5th edition, McGraw-Hill Book Company, 1989.
2. Kluger Y, Douglas B.P, Raves J.J et al. Delayed rupture of the spleen- myths facts and their importance: case reports and literature review. J Trauma 1994; 36:568
3. Cocanour C.S, Frederick A.M, Ware D.N et al. Delayed complications of non-operative management of blunt adult splenic trauma. Arch Surg. 1998;133:619-625.
4. Hiraide A, Yamamoto H, Yahata K et al. Delayed rupture of the spleen caused by an intrasplenic pseudoaneurysm following blunt trauma: case report. J Trauma. 1994;36:743-744.
5. Olsen WR, Polley TZ Jr. A second look at delayed splenic rupture. Arch Surg 1977;112:422.
6. Farhat GA, Abdu RA, Vanek VW. Delayed splenic rupture: Real or imaginary? Am Surg 1992;58:340.
7. Black JJ, Sinow RM, Wilson SE, Williams RA. Subcapsular haematoma as a predictor of delayed splenic rupture. Am Surg. 1992;58:732-735.
8. Pachter HL, Hofstetter HR, Elkowitz A et al. Traumatic cysts of the spleen, the role of cystectomy and splenic preservation: experience with seven consecutive patients. J Trauma. 1993;35:430-436.
9. Kennedy JA, Majury C, Kelly I, Kirk SJ. Post traumatic pseudoaneurysm of an intrasplenic segmental artery: a mechanism of delayed splenic rupture. Injury. 1999;30:535-536.
10. Sartorellie KH, Frumiento C, Rogers FB, Osler TM. Nonoperative management of hepatic, splenic, and renal injuries in adults with multiple injuries. J Trauma 2000;49:56-62
11. Sugg SL, Gerndt SJ, Hamilton BJ, Francis IR, Taheri PA, Roodriguez JL. Pseudoaneurysms of the intraparenchymal splenic artery after blunt abdominal trauma: A complication of non-operative management. J Trauma 1995;39:593-597

Crossword



Pre-Hospital Care Crossword
by Giles Cheeseman, Medical Student, Edinburgh University.
Liverpool Hospital, September to October 2000

Across

4. (& 14 down). Which analgesia is contraindicated in caisson disease? (7, 5)
5. The first traction splint devised in World War 1, decreased deaths from open femur fractures by 60%. (6)
8. What is the commonest cause of a "flat baby"? (7)
9. Whose triad consists of distended neck veins, hypotension and muffled heart sounds? (4).
11. The _____ formula is "% burn x mass (kg) x 4" (8)
15. Loss of power & pain sensation below injury with preservation of touch & proprioception is seen in which cord syndrome? (8)
16. Amps and Newtons end their Society (3)
18. Bradycardia, a wide pulse pressure with a low systolic BP, a decreased urine output with warm, dry peripheries are symptoms of what type of shock? (10)
19. A very heavy method of being shown the way in 16 across (4).
20. Time that comes first (6)

21. (& 7 down) The ____ and _____ formula is "%burn x mass (kg) x 0.5 " (4, 8)
22. A collection of blood in the anterior chamber of the eye. (8).
23. _____'s triad consists of unilateral fracture of femur, ipsilateral spleen injury and contralateral head injury? (7)

Down

1. In which response is an increase in intracranial pressure seen with a hypertension and bradycardia? (7)
2. An alternative to (13 across) (10)
3. Which splint exerts counter-pressure against the symphysis pubis? (5)
5. "Grow old. A period of history. A long time" - an important pre-hospital skill. (6)
10. See 17 down
12. See 17 down
13. Most commonly used anti-arrhythmic drug? (UK / Australian spelling) (10)
17. (&12 down & 10 down) This achieves potentially complete pain relief for mid-shaft femur fractures. (7,5,5)

Meetings

Trauma 2001: A Joint Meeting of the Australasian Trauma Society and the Trauma Association of Canada (incorporating the 3rd Australasian Fluid Symposium) is to be held 2-4 March 2001 at the Sydney Convention Centre.

Themes will include: State of the Art Trauma Care, Latest in Fluid Therapy, Trauma Systems, Paediatric Trauma, Difficult Trauma Areas and Free Paper / Poster Sessions.

For further information please contact Trauma 2001 Secretariat: Conference Action Pty Ltd. PO Box 1231 North Sydney NSW 2059. Tel: 02-99568333. Fax: 02-9956 5154 Email: confact@conferenceaction.com.au

Definitive Surgical Trauma Care Course (DSTC) Sydney (For Surgeons Only Very limited)
31st July and 1st August, 2001
Email: charmaine.miranda@swsahs.nsw.gov.au

SWAN 9

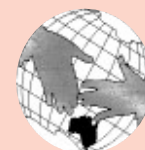SWAN 9 will be held on the 3rd and 4th of August, 2001, bringing to you a number of world leaders in trauma care from overseas. Sorry registration is limited, so get in early!

Contact: Thelma Allen

Email: thelma.allen@swsahs.nsw.gov.au

Phone: 02 9828 3927

<http://www.swsahs.nsw.gov.au/livtrauma>



International Symposium on the Abdominal Compartment Syndrome

August 2nd, 2001 Liverpool Hospital

Contact: Email: charmaine.miranda@swsahs.nsw.gov.au





Case of the Month



M	22 year old male driver	Secondary survey
I	Upper Abdominal pain,	Abdomen -Tender RUQ -Marked Guarding in the Upper Abdomen
S	P110/m, BP 90, RR 22/m GCS 15	-BS reduced -PR NAD
T	Cervical collar, oxygen	
Primary Survey		Summary of Investigations
A	Intact	C Spine Normal CXR Normal
B	RR 22/m, SaO2 97% on 10L, Ø AE and BS on L	Pelvic X-ray Normal FAST Positive in all 3 views Small Amount of free fluid
C	P118/m, BP 95/82, all pulses intact and symmetrical.	What is your patient management. He has received 2L of Haemaccel and 1L of Saline, His BP has fluctuated to 80mmHg on 2 occasions. His abdomen is not distended.
D	GCS 15, pupils equal and reactive.	

Review of last issue's case of the Month

M 26 year old MBA.
I Abdominal and limb injuries
S RR 30, ↓ AE on R side,
P100/m, BP 140/90, GCS 15

Extremities -RUL shoulder pain
-RLL abrasions to R hip

T Cervical Collar, oxygen,

Primary Survey

A Intact
B RR 18/m, SaO2 100% on 10L, ↓ AE and BS on R
C P115/m, BP 156/82, all pulses intact and symmetrical.
D GCS 15, pupils equal and reactive.

Summary of Investigations

C Spine Normal
CXR Raised Right Diaphragm
Pelvic X-ray Normal

Management? What would you do from here? What are the key priorities?

The clinical evidence is clear. There are marked abdominal signs in a haemodynamically borderline patient. The injury is more likely to be a liver fracture but that in isolation is not going to give me such an abnormal CXR.

The priority is to establish the nature of intra-abdominal injury, which can be done with a CT (unless you suspect a bowel injury - then

do a DPL), but unfortunately the other injury which is probable is a right diaphragmatic rupture. This is difficult to diagnose definitively. Should you proceed with a CT, try an ultrasound, go for a laparoscopy (after chest drain insertion)? It's very complex and the probability of error increases the more tests you undertake.

Because of the marked abdominal signs and the grossly abnormal CXR a decision to progress directly to laparotomy was made. While this is potentially associated with a non therapeutic laparotomy rate of about 30%, given the difficulty of establishing a diagnosis of diaphragmatic rupture laparotomy is the safest course.

At surgery the patient had a large hole in the right diaphragm and was bleeding from a liver fracture between segment 6 and 8 of the liver. This was successfully oversewn and the patient made an uneventful recovery.

Letter to the Editor

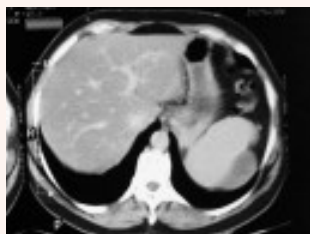Tricky Case

Dear Michael,
I am writing seeking advise regarding a 53 year old male car crash victim, who in May 1999 sustained a splenic haematoma which is being treated conservatively. A year has passed now and there is incomplete resolution. He is wondering when he can return to normal activities. The CT scan report, showing a lateral capsular haematoma, measuring 5.6x2.6cm, compared to 5.7x3.0 previously. (Figure 1). I have certainly had one patient who ruptured a splenic haematoma although this was 4 weeks

afterwards. This patient almost exanguinated before it could be dealt with adequately.

I am not sure whether you know of any cases that have progressed in this manner. Normally I would have expected complete resolution by now. I look forward to your view.

Dr William B Ross
General Surgeon
Coffs Harbour
June 2000



Reply

Bill, Thank you for sharing this interesting case. It is difficult to be dogmatic about a such a rare, but well recognised complication. Based upon Pachter's experience I would re CT the patient in 3 months. If the cyst remains >5cm an image guided aspiration should be undertaken. If this fails a laparoscopic or open cystectomy may be preferable. If the cyst size is less than 5cm observation is probably preferable warning patient about body contact sports.

Michael Sugrue

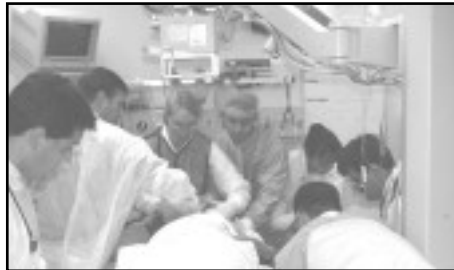The Nurse in the Trauma Team

Maria Seger Trauma Nurse Co-ordinator (written in July 2000)

Nurses are an essential part of the trauma team. Emergency nurses tend to be a fairly constant group and have an excellent knowledge of policies and procedures in the resuscitation room, ensuring smooth facilitation of trauma care. This is in contrast to medical personnel who respond from various disciplines to attend trauma and frequently rotate between hospitals. The trauma nurse plays a critical role in the assessment of the trauma patient. This assessment spans from the time of the patient's arrival at the hospital, to discharge into the home and rehabilitation setting. It is important for nurses to be knowledgeable about trauma assessment, mechanism of injury, and the high risk and frequent complications that threaten the trauma patient.

Optimal communication is an essential ingredient for trauma team function. In a recent study at Liverpool Hospital evaluating the role of the trauma team leader, it was identified that "poor communication was one of the major deficiencies of the team leader." (1). Upon pre hospital notification of an incoming patient the trauma team is activated (ideally activations should be no longer than 10 minutes prior to arrival). The nurses are required to proceed to the resuscitation room and communicate with the team leader and the other members of the trauma team. In order to avoid confusion and perform efficiently, the members of the trauma team wear name tags labelled according to their role. There are three key nurses on the team, Airway, Procedure and Scribe.

Nurses are allocated to their specific roles at the beginning of each shift and nurses roles are interchangeable from shift to shift. Additional nurses are often required for multiple trauma. The nurses response to trauma team activations are excellent. A recent review of the nursing performance as part of the trauma team at Liverpool found all three nursing members are present on arrival of the patients in 94% during day shift and 80% after hours (2). Pre arrival preparation is vital.



The Trauma Team in action

AIRWAY NURSE:

The airway nurse is responsible for airway equipment including preparation of emergency airway procedures. Together with the airway doctor, the nurse calculates drug dosages and prepares the appropriate drugs. This is especially critical when paediatric trauma is involved. Stabilization of the cervical spine may not be achieved in the prehospital setting and it is the airway nurses responsibility to ensure that the correct size collar is available and fitted correctly. Once the patient arrives, the nurse assists the doctor with maintaining an airway, drug administration, cricoid pressure, securing the tube and ensuring monitors are connected appropriately. The airway nurse ensures all portable equipment is ready if the patient needs to be moved to another facility within the hospital eg. CT scanner.

PROCEDURE CIRCULATION NURSE:

The procedure / circulation nurse works in conjunction with the procedure / circulation doctor who is the surgical medical officer. The circulation nurse according to the pre hospital information ensures that all equipment is available. Warm fluids are primed in a blood pump set and the Level 1 rapid infuser on standby. Blood is available in the resuscitation room and should be at hand. Procedures performed in the resuscitation room include emergency cricothyroidotomy, packing of major facial fractures, saphenous vein cut down, diagnostic peritoneal lavage, urinary catheter insertion, chest drain insertion, emergency room thoracotomy and stabilization of fractures. Intraosseous needles are available for paediatric trauma. On arrival of the injured patient, the procedure circulation nurse assists with removal of

clothing and provides warm blankets to prevent hypothermia. Monitoring is attached to the patient and assistance is given with securing intravenous lines. The procedure / circulation nurse and the procedure / circulation doctor liaise regarding procedures. During major trauma, additional assistance may be required to facilitate the use of the Level 1 rapid infusion device.

SCRIBE NURSE:

The scribe nurses role may appear simple, but in actual fact it is a very complex role. Upon pre-hospital notification of arrival of the trauma patient, it is the scribe nurses responsibility to notify the operating theatres via a speed dial phone number. This number contacts the operating theatre supervisor who will be provided with the following information.

M -Mechanism
I - Injury
S - Signs
T - Treatment

This facilitates rapid transportation to the operating theatre when necessary.

It is the scribe nurses responsibility to obtain patient identification labels from the clerical personnel and attach two armband labels to the patient. The scribe nurse documents vital signs every 15 minutes (or every 5 minutes in the unstable patient). The nurse ensures all fluids and medications are documented and maintains chronological record of events and procedures of the resuscitation.

The nursing members of the trauma team are a strong link in trauma care. They must be familiar with roles, which may vary from hospital to hospital. They should communicate clearly within the team and to staff in other parts of the hospital. A well oiled team is associated with good patient outcome and a warm feeling of job satisfaction.

References:

1. Sugrue M Seger M, Kerridge R, Sloane D, Deane S. A prospective study of the performance of the trauma team leader J Trauma 1995 38:79-82
2. Lu WH, Kolkman K, Seger M, Sugrue M. An evaluation of the trauma response in a major trauma hospital in 100 patients Aust NZ J Surg 2000; 70:329-332





Emergency Airway Management for Trauma Patients

Helen Oliver, Medical Student Michael Parr, Staff Specialist.
Liverpool Hospital

Securing a patent airway is the first and most important priority in the management of the trauma patient. In the presence of airway obstruction, hypoxia leading to circulatory arrest can be expected to occur within 4-10 minutes, with irreversible central nervous system damage following quickly. Effective airway management requires an understanding of functional airway anatomy and physiology, and the skills to assess and intervene rapidly when airway obstruction and ventilatory compromise occur. The basic skill of maintaining an open airway cannot be over emphasised, and should be mastered before attention is directed to advanced airway management techniques. Airway compromise arises from either direct injury to the airway, or neurological damage or depression. Airway compromise can occur insidiously or suddenly, and the management will depend on the history and the findings on examination. The trauma situation is complex and often there is little time for deliberation. Therefore, a rapid systematic approach to assessment and management is required. The following represents one approach to dealing with the airway in major trauma.

AIRWAY ASSESSMENT

The assessment should begin with a history of the acute event and any pre-morbid condition of relevance. Examination involves looking, listening, and feeling to assess the degree of

Table 1. Airway assessment: Signs to look for and their interpretation:

Sign	Interpretation
Normal speech	Reassuring (so far)
Abnormal speech	Partial obstruction at laryngeal level
- Hoarse	Imminent respiratory decompensation
- Too breathless to talk	Lower airway obstruction
- Wheeze and dyspnoea	
No air movement or breath sounds	Total airway obstruction
Inspiratory or expiratory noise	Partial obstruction at the pharyngeal level
- Snoring	
- Stridor	Partial obstruction at the laryngeal or tracheal level
Reduced tidal volume with increased intercostal and diaphragmatic movement	Partial upper airway obstruction
Rate of ventilation	
- Bradypnoea	CNS depression or injury
- Tachypnoea	Upper or lower airway problems
Agitation and central cyanosis	Hypoxaemia

airway obstruction and ventilatory compromise.

Oxygen therapy

High concentration oxygen is indicated in all trauma patients where tissue oxygenation is impaired and to increase the oxygen reservoir before any airway procedure (preoxygenation). The most efficient method for delivering a high oxygen concentration in the spontaneously breathing patient is to use a tight fitting mask, with a wide bore circuit and reservoir bag that is being fed with oxygen at a flow rate in excess of the patient's minute ventilation. In the intubated patient with an airtight tracheal tube, delivery of 100% oxygen can be ensured and positive end- expiratory pressure (PEEP) can be used in an attempt to improve oxygenation.

Airway Management

Airway patency can be established and controlled by an escalating sequence of:

- basic manual and positional methods
- use of airway adjuncts
- definitive airway techniques
 - tracheal intubation
 - cricothyroidotomy
 - tracheostomy

Although basic airway manoeuvres are vitally important and will often successfully relieve airway obstruction and save lives, continued airway patency and security in the unconscious and severely injured trauma patient can often only be guaranteed by placement of a cuffed tracheal tube. A comprehensive discussion of the full range of airway procedures can be found elsewhere(1) but the following principles will generally suffice.

Basic airway manoeuvres

• Limited to chin lift and jaw thrust . All blunt trauma patients are suspected to have a cervical spine injury until proven otherwise. The use of the head tilt is therefore contraindicated as immobilisation of the cervical spine must be maintained.

Airway adjuncts

• The oropharyngeal (Guedel) airway. Prevents backward displacement of the tongue in the unconscious patient and usually provides relief for the rescuer from having to apply prolonged chin lift or jaw thrust. The

airway does not protect against aspiration of foreign material. Potential Complications: Provoking retching, vomiting or laryngeal spasm if active reflexes are present.

- The nasopharyngeal airway. Passed through the nose so that the tip lies behind the tongue in the laryngopharynx just above the glottis. Nasopharyngeal airways do not protect against aspiration of foreign material. Easier to place than oral airways and are better tolerated by the obtunded patient. Potential complications: Nasal haemorrhage. Inadvertent passage into the cranial cavity through a base of skull fracture. Provoking retching, vomiting or laryngeal spasm.

Advanced airway manoeuvres

Tracheal intubation provides the most reliable, clear and secure airway through which positive pressure ventilation can be applied and the airway can be suctioned. The cuff around the distal end of the tube prevents gas leakage during ventilation and guards the tracheobronchial tree from aspiration of foreign material.

Orotracheal intubation using direct laryngoscopy

Unless there are specific contraindications this is the most common technique for placing a tracheal tube via the oral route.

Indications

- Airway obstruction or potential airway obstruction
- Airway protection in patients at risk of aspiration of foreign material.
- Patients requiring positive pressure ventilation for therapeutic reasons such as controlled ventilation for head injury.

Table 2. Additional airway assessment to rapidly predict the ease of intubation:

Sign	Interpretation
Trauma to the face and neck	All are likely to make intubation and airway management more difficult
Small chin, beards, poorly fitting dentures, loose teeth/buck teeth/ peg teeth	
Mouth opening	
Visible structures on mouth opening	Less than 4 cm (adult) between upper and lower incisors - difficult to intubate
Range of neck movement	Blunt trauma patients will have their necks immobilised making intubation more difficult.

Potential Complications

- Trauma to lips, teeth, tongue and structures in the pharynx or larynx.
- Inducing vomiting, which may lead to aspiration, coughing and laryngospasm.
- Oesophageal intubation.
- Sympathetic stimulation with hypertension and tachyarrhythmias.
- Vagal stimulation causing bradycardia
- Exacerbation of cervical spine injury.

Orotracheal intubation is usually performed during a rapid sequence induction (RSI) of anaesthesia with a hypnotic and a neuromuscular blocking agent, with cricoid pressure applied and with the head and neck in manual in line immobilisation (MILS). Tracheal intubation may also be accomplished by a variety of awake, local anaesthetic techniques, which require a co-operative and relatively stable patient. These techniques are beyond the scope of this article.

Cricoid pressure

In 1961, Sellick described cricoid pressure as a method of reducing the risk of regurgitation of gastric contents and preventing gastric inflation during ventilation under general anaesthesia (2). Cricoid pressure may also improve the view at laryngoscopy. Backward pressure on the cricoid cartilage result in occlusion of the oesophagus against the vertebral body of C5. If incorrectly applied cricoid pressure will increase the difficulty of intubation.

Gum elastic bougie

The gum elastic bougie is a long thin introducer with an angled tip used in cases of difficult intubation and poor laryngoscopic view. The distal end of the bougie if angled to 45° and passed directly behind the epiglottis will usually pass through the vocal cords into the trachea. Tracheal placement of the bougie is confirmed if the bougie is felt to "click" across the tracheal rings or to be "held up" in the bronchial tree. Leaving the laryngoscope in the mouth, the tracheal tube is railroaded over the bougie into the trachea. Using this type of introducer is likely to be more successful in difficult intubations than using short stiff tube introducers (3).

Oral intubation aided by the McCoy levering laryngoscope
When attempting to intubate the patient with

the head and neck in neutral alignment laryngoscopy will often result in visualisation of the epiglottis only. A modification of the standard curved (Macintosh) laryngoscope blade, the levering laryngoscope, has been described and is likely to improve the chances of successful intubation on the first attempt (4).

Unable to intubate situations

If there is failure of intubation there are a number of alternatives. The clinical situation will dictate which option is most appropriate. Oxygenation remains the priority and provided this is assured and the situation is stable reattempting oral intubation may be tried. Devices such as the Laryngeal Mask

laryngeal opening, leaving the tube orifice in close proximity to the glottic opening. A modification, the Intubating Laryngeal Mask (ILM) also provides the option of blind or fibreoptic-guided placement of a tracheal tube through the device.

The Combitube oesophageal/tracheal airway

The Combitube is a double lumen tube which is designed to ventilate the patient's lungs whether the tube enters the trachea or the oesophagus. The "tracheal" channel has an open distal end and the "oesophageal" channel has a blind end with openings at supraglottic level. There is a small volume distal cuff and a high volume (100 ml) cuff designed to occupy the laryngopharynx.

Cricothyroidotomy

This is the emergency surgical airway of choice in trauma patients. Access is achieved through the cricothyroid membrane. A size 6.0 tracheostomy or tracheal tube is suitable for adults and is placed. A bougie may aid placement if a tracheal tube is used.

Tracheostomy

Tracheostomy takes more time to perform than cricothyroidotomy and is therefore less appropriate in the emergency situation. However, in laryngeal and upper trachea injuries it may be required as cricothyroidotomy may not provide access to the airway or may disrupt the damaged airway during the procedure.

Summary

Airway management is generally straightforward but is often made more complex by the stressful environment of the Emergency Department. For optimal management of the severely injured the clinician requires a working knowledge of a wide range of airway management procedures. While some of these basic techniques are easily learnt, the more advanced procedures require formal training and regular practice to maintain skill. In the absence of adequate oxygenation any interventions other than those aimed at the airway are redundant.

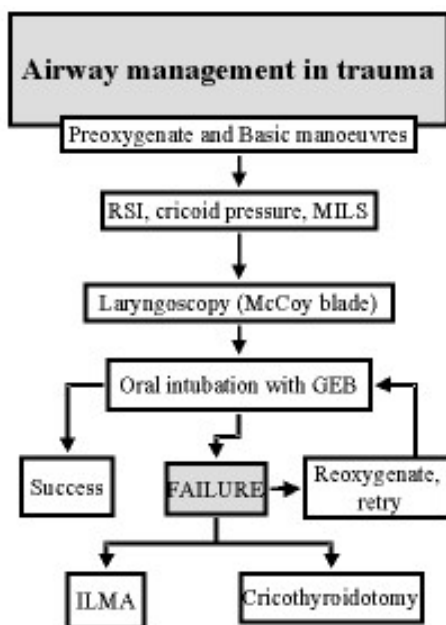


Figure 1. Algorithm for airway management in trauma patients

Airway and Combitube offer alternatives that provide oxygenation and ventilation, but without the security of a cuffed tube in the trachea. In unstable and hypoxic patients the most effective way of securing the airway will be by cricothyroidotomy or tracheostomy. A suggested algorithm is presented in Figure 1.

The Laryngeal Mask Airway (LMA)

This airway consists of a wide bore tube with an elliptical inflation cuff at the distal end which is designed to form a seal around the

References

1. Parr MJA, Nolan JP, Baskett PJF. Chapter 2. Airway Management. In Cambridge Textbook of Accident and Emergency Medicine. Cambridge University Press 1997.
2. Sellick BA. Cricoid pressure to control regurgitation of stomach contents during induction of anaesthesia. The Lancet 1961; 2:404-406.
3. Gataure PS, Vaughan RS, Latto IP. Simulated difficult intubation. Comparison of the gum elastic bougie and the stylet. Anaesthesia 1996;51:935-8.
4. McCoy EP, Mirakur RK. The levering laryngoscope. Anaesthesia 1993; 48: 516-519