

Contents:

- ⊕ Factor 7a
- ⊕ Diaphragmatic Injury
- ⊕ Review of last month's case of the month
- ⊕ What's new in Trauma
- ⊕ Backchat
- ⊕ Meetings

TRAUMA

Grapevine



Introduction

Let us reflect for a moment on the leading causes of death: cardiac disease, cancer and trauma. Imagine the following proposal - from January 2003 the population of Melbourne and Sydney will be served by 2.5 and 3.0 full time equivalent (FTE) cardiologists. It has been suggested that the system will be very organized with excellent prehospital triage bringing patients with suspected myocardial infarction to either one of two hospitals in Melbourne, and one of six in Sydney. In Sydney the 3.0 FTE cardiologists will however only be working at 3 hospitals - one in both Liverpool and Westmead, and one to be appointed to St George. It is felt however that the cardiologists will be able to oversee the care of all patients in their respective hospitals. There will of course be excellent links with the smaller hospitals, and good rural support and liaison. To help the cardiac departments each cardiologist will have a secretary and a part time case manager. To ensure that positions will be competitive there will only be a 300% reduction in salary compared to equivalent private practice specialist. This will result in a significant lower tax burden for the new positions.

The new cardiologist should ideally be multi-lingual as there are no trainees in cardiology in Australia currently, therefore overseas recruitment may be necessary. It is anticipated that this system will reverse the current

performance in the area where about 30% of deaths are considered potentially preventable.

Has the editor been partaking of early Christmas festivities when writing this? Sounds ridiculous? Not if you substitute Trauma Surgeon for cardiologist!! Australia urgently needs a major revision of its trauma service provision, and incentives are required in many particular areas to encourage trainees to take up the specialty. Initiatives have begun, with the NSW Institute of Trauma and Injury Management, however, it is vital that in NSW the initial progress is maintained and real Trauma Directors appointed to serve the population. Remember, while it is the police who protect your safety and firefighters your property, trauma teams save your life!

Trauma requires specific skills and knowledge in so many areas. This issue deals with two such areas: management of thoracic abdominal stabs wounds, and understanding the concept of major blood transfusion.

On behalf of all in Trauma I would like to wish you all a happy Christmas and a peaceful New Year. I would like to thank B|Braun for their support to trauma education with the Trauma Grapevine, which will enter its 9th year in 2003.

Michael Sugrue



Use of Recombinant Factor VIIa in a Patient with Recalcitrant Coagulopathy

Matthew D. Smith, B.A. Trauma Student College of Ohio Toledo
Michael Sugrue Trauma Liverpool

Introduction

Managing uncontrolled haemorrhage is crucial to decreasing mortality in surgical and trauma patients. According to a recent study by Sauaia et al exsanguination accounts for 39% of all hospital deaths on trauma patients¹. In addition, many critically ill patients suffer from some degree of multifactorial coagulopathy, further complicating management of their bleeding. The nature of this

coagulopathy has been well described by Martinowitz et al and includes non-DIC consumptive coagulopathy, excessive fibrinolysis, dilutional coagulopathy due to large amounts of infused fluids, hypothermia, acidosis, and multitransfusion syndrome².

Treatment of this haemorrhage includes several modalities. Infusion of packed red blood cells, fresh frozen plasma, and platelets can



Diaphragmatic injury in thoraco-abdominal stab wounds: Case discussion and review of the literature

Harpreet Malhi & Nipa Miah Final Year Medical Students University of Leeds Michael Sugrue Trauma Liverpool.

Case Report

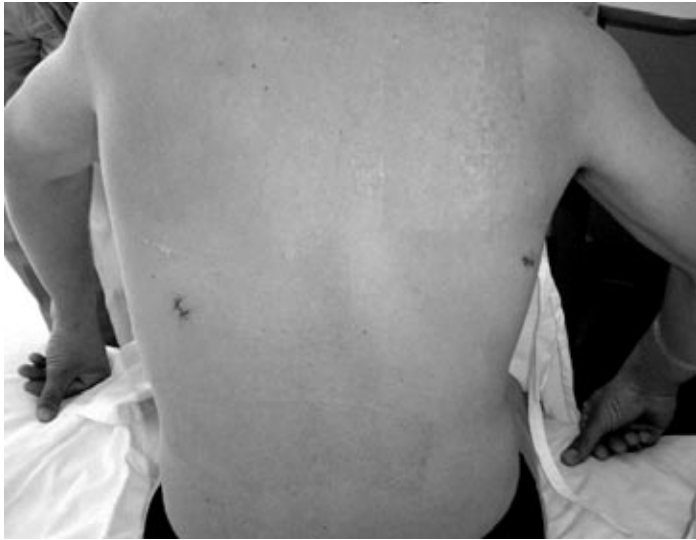


Figure 1 Male with two stab wounds

- M** 22 year old male
- I** Stab
- S** P 90/m, BP 120/80mmHg, RR 22/m GCS 15
- T** Rapid transport, oxygen

Primary Survey

- A** Intact
- B** RR 22/m, SaO2 99% on 10L, Good air entry
- C** P 90/m, BP 120/82mmHg, Well perfused
- D** GCS 15, pupils equal and reactive

Secondary survey

Chest Two stab wounds: Right 6th ICS post axillary line
Left 7th ICS post axillary line

Abdomen - Soft

Summary of Investigations

- CXR** Normal
- FAST** Negative

What would you do now? The patient is obviously stable from a haemodynamic viewpoint. Write down what you would DO. You have the option below of making 3 choices. Will you manage the left and right stab wounds differently?

- 1 _____
- 2 _____
- 3 _____

Please read on and decide if you would do anything differently having read the review below.

Review of Management of Diaphragmatic Injuries

Potential intra-abdominal injuries inflicted by stab wounds are often self-evident by the location of the wound. However, penetrating stab wounds to the back and flank are rarely associated with significant internal organ injury. If stabbed anteriorly, 44% of patients will have significant intra-abdominal injury, compared with 7-15% and 19-29% if stabbed in the back or flank respectively. In fact, depending on case selection, a flank stab wound is associated with significant intra-abdominal injury in as few as 3% of patients. This is due to the area containing many protective structures such as the bony skeleton (scapulae, iliac crests, ribs of the lower thorax, vertebral column), and the para-spinal muscles of the back (such as the psoas, latissimus dorsi, the quadratus lumborum, and the lateral oblique muscles of the flank).

The most commonly injured organs in an anterior abdominal stab wound are the liver, small bowel and the diaphragm. Leppaniemi et al found that in 209 patients with anterior abdominal stab wounds 22% had sustained injuries to the liver, 15% had damage to their small bowel and 11% had damage to their diaphragm [1]. Ditmars and Bongard found similar injuries at laparotomy, with liver, colon and diaphragm being the most commonly injured organs [2]. The most commonly injured abdominal vessels were the inferior vena cava and the portal vein [1]. The most commonly injured structures in the posterior abdomen were retroperitoneal structures such as the kidney, pancreas and diaphragm.

The thoraco-abdominal region is the area bounded anteriorly and superiorly by the nipples, the scapular tips posteriorly, and inferiorly by the costal margin. Any penetrating wound to this area should be suspected of causing damage to the diaphragm until proved otherwise, as approximately 13-19% of penetrating wounds to this area will affect the diaphragm. Penetrating injuries of the diaphragm mainly involve the left side of the diaphragm due to the protective effect of the liver on the right side and the right-handedness of the knife-holding assailant [3]. Many of these patients will have injured other organs, the most common being the lung resulting in either a haemothorax or pneumothorax. Therefore, our patient above has approximately 15% chance of significant injury.

What is the optimal way of diagnosing diaphragmatic injury?

Serial abdominal examination has its advocates, and if peritoneal signs develop these patients should undergo laparotomy. However, there are two main problems with this: maintenance of continuity of care, and silent diaphragmatic injury [4].

Studies emphasize the importance of early diagnosis and repair of injuries of the left diaphragm, as mortality rates from diaphragmatic injuries can be up to 20-48% [5]. Patients with isolated diaphragmatic injuries are difficult to diagnose as they may present as an acute abdomen or with signs of a diaphragmatic hernia i.e. bowel obstruction and cardio-respiratory distress. However, many patients show no clinical signs so diagnosis may be missed without radiological investigations [6].

The simplest, most useful investigation used to diagnose diaphragmatic injury is the CXR. In one study a CXR was diagnostic in 13% (diagnosed by elevated diaphragm and presence of a hollow viscus in the chest) and abnormal in 76% of cases. The diagnostic accuracy of the chest radiograph may be increased by inserting a naso-gastric tube with a radio-opaque tip when a herniated stomach is suspected. However, in uncomplicated diaphragmatic perforations, radiological diagnosis is more difficult [6]

FAST (Focussed Assessment Sonography in Trauma), whilst obviously useful for detecting free intra-peritoneal blood, will not diagnose diaphragmatic injury [7]. DPL (Diagnostic Peritoneal Lavage) can be used to determine the presence of small amounts of intraperitoneal blood (positive if RBC greater than 10,000mm³, - 1/10 the blunt values). Triple or double contrast CT is not reliable.

Diagnostic laparoscopy is the procedure of choice and on occasion it may be possible to fix the diaphragm laparoscopically [8]. Remember, there is a risk of tension pneumothorax from abdominal gas insufflation and ideally a chest tube should be inserted before gas insufflation is undertaken.

Thoracoscopy is a very useful and simple procedure. With the increasing use of bronchial blockers, double lumen intubation is usually not required. While gas insufflation can be used it can obviously result in tension pneumothorax and is not the preferred technique.

Thoracoscopy has been used to identify diaphragmatic injury in the past but has limitations due to equipment availability and expense [9]. It has some potential advantages:

- 1 Provides an excellent view of the diaphragm; and
- 2 It allows evaluation of intra-thoracic injuries like intercostal arteries and pulmonary haemorrhage (visualization of the pericardial sac allows exclusion of cardiac injury).

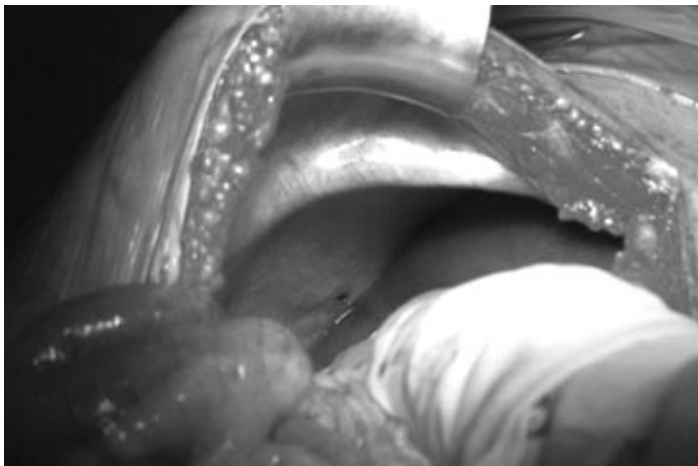

Figure 2 Classical Diaphragmatic laceration on right side

References

[1] Leppaniemi AK, Voutilainen PE, Haapiainen RK. Indications for early mandatory laparotomy in abdominal stab wounds. *BJS* 1999; 86: 76-80

[2] Ditmars ML, Bongard F. Laparoscopy for triage of penetrating trauma: the decision to explore. *J Laparoendoscopic Sur* 1996; 6(5): 285-91

[3] Frantides CT, Carlson MA. Laparoscopic repair of a penetrating injury to the diaphragm: a case report. *J Laparoendoscopic Sur* 1994; 4(2): 153-6

[4] Ortega AE, Tang E, Froes ET, Asenio JA, Katkahouda N, Demetriades D. Laparoscopic evaluation of penetrating thoracoabdominal traumatic injuries. *Surgical Endoscopy* 1996; 10(1): 19-22

[5] Uribe RA, Pachon CE, Frame SB, Enderson BL, Escobar F, Garcia GA. A prospective evaluation of thoracoscopy for the diagnosis of penetrating thoracoabdominal trauma. *J Trauma* 1994; 37(4): 650-4

[6] Demetriades D, Kakoyiannis S, Parekh D, Hatzitheofilou C. Penetrating injuries of the diaphragm. *BJS* 1988; 75: 824-6

However, the dilemma with thoracoscopy is if one finds a diaphragmatic laceration, what does one do with the abdomen? Our policy is to perform a laparotomy.

What are the sequelae of a missed injury?

Penetrating stab wounds to the back and flank in the stable patient are rarely associated with significant retroperitoneal or abdominal injuries. However, the rare injury, if missed, can have devastating consequences thus presenting a diagnostic challenge in the identification of these injuries [6]. Thoraco-abdominal penetrating wounds tend to be more lethal with nearly twice as high mortality than those with isolated chest wounds.

The natural history of unrepaired diaphragmatic injuries is unknown. Most penetrating diaphragmatic tears are less than 2cm long [6]. Diaphragmatic herniation of intra-abdominal viscera through a penetrating injury of the diaphragm is relatively uncommon, especially as there maybe a long latent period before symptoms develop. The colon, stomach, omentum and small bowel are herniated in decreasing order of frequency. Late complications relate to strangulation of abdominal viscera through the defect. The pressure gradient between the abdominal and thoracic cavity may enlarge the defect and progressive herniation may take place [6]. Late morbidity is commonly catastrophic with mortality rates from 20-48% [10]. Strangulation is fatal in up to 80% of patients [11]. It is probable however, that the majority of missed diaphragmatic injuries heal without problems.

Having read the article please indicate what you would do with this patient. For our recommendations please see below.

Our recommendation would be diagnostic laparoscopy, with insertion of chest tube in the operating room just before the commencement of the laparoscopy, with antibiotic prophylactic cover. In our patient this was done 2 hours after admission, there was a left diaphragmatic laceration 2.5cm which was oversewn at laparotomy, and the patient was discharged 6 days later.



[7] Boulanger BR, Kearney PA, Tsuei B, Ochoa JB. The routine use of sonography in penetrating torso injury is beneficial. *J Trauma* 2001; 51(2): 320-5

[8] Gunning KA, Moont M, Sugrue M. Laparoscopic repair of penetrating intra-abdominal injuries. *BJS* 1995; 82(7):920

[9] Degiannis E, Levy RD, Sofianos C, Potokar T, Florizoone MG, Saadia R. Diaphragmatic herniation after penetrating trauma. *BJS* 1996; 83(1): 88-91

[10] Kawahara N, Zantut LF, Poggetti RS, Fontes B, Bernini C, Birolini. Laparoscopic treatment of gastric and diaphragmatic injury produced by thoracoabdominal stab wound. *J Trauma* 1998; 45(3): 613-4.

[11] Albrecht RM, Vigil A, Schermer CR, Demarest GB 3rd, Davis VH, Fry D. Stab wounds to the back/flank in haemodynamically stable patients: evaluation using triple-contrast computed tomography. *Am Surg* 1999; 65(7): 683-8



Use of Recombinant Factor VIIa in a Patient with Recalcitrant Coagulopathy

Continued

replenish lost blood products. Definitive management, however, is often surgical. Primary repair of the bleeding vessel, ligation, packing, fibrin glue, cauterization, argon laser coagulation, and delivery of clotting factors can all be implemented. The introduction of recombinant DNA technology and synthetic clotting factors such as recombinant factor VIIa has added yet another weapon to the surgeon's haemostasis arsenal.

Haemostasis Physiology

Normal haemostasis is achieved through a complex interaction of the blood vessel endothelium, platelets, and clotting factors³. When damaged, the vascular endothelium uses von Willebrand factor to facilitate platelet adhesion. Endothelial cells also bind factors Xa and IXa, release tissue factor, and secrete inhibitors of plasminogen activator to further promote clotting. After damage to the endothelium and exposure of normally sequestered cells to blood, platelets adhere to the area and change shape, secrete various molecules, and aggregate. All of these actions seek to stop the bleeding. Finally, an exceedingly complex interaction of endogenous proteins in the blood known as factors leads to the production of thrombin, which in turn converts fibrinogen to fibrin. Fibrin then crosslinks to anchor platelets in place and achieve haemostasis.

Recombinant factor VIIa (rFVIIa) (NovoSeven, Novo Nordisk A/S, Bagsvaerd, Denmark) facilitates haemostasis by complexing with tissue factor (TF), an endogenous lipoprotein found in the vessel intima⁴. This TF- rFVIIa complex forms an integral part in the extrinsic pathway of blood coagulation. After complexing with TF, rFVIIa becomes enzymatically active and converts factor X to factor Xa. Factor Xa then leads to the conversion of prothrombin to thrombin, a powerful haemostatic agent. Thrombin functions to convert inactive fibrinogen to fibrin. Fibrin is responsible for cross-linking platelets and is the end product of the coagulation cascade. Thrombin also activates fibrinolytic, vasoactive, and cytokine mediators to limit the haemostatic response and prevent uncontrolled clotting.

Case Report

Our case begins with a thirty-two year old pregnant female who presented with complaints of nausea and vomiting, dark urine, decreased appetite and generally "feeling unwell." Until that point she had had an uneventful pregnancy, and had scored an 8/8 on a biophysical profile two days previously. Upon physical examination she had right upper quadrant tenderness and appeared jaundiced. A cardiotocograph showed late decelerations with a fetal heart rate of 110 and poor variability. An emergent Cesarean section was performed and a large amount of vaginal blood loss was noted. The baby itself was perfectly healthy. Blood chemistries revealed elevated liver enzymes.

Large amounts of oxytocin and ergonovine maleate as well as vaginal packs failed to control the bleeding. The following day an exploratory laparotomy revealed diffuse abdominal bleeding without any focus. At this time the patient was deemed to be frankly coagulopathic. Another exploratory laparotomy the next day showed generalized oozing from the abdomen and a firm uterus. Again, no focus of bleeding was found and the patient was given 5.0g of aminocaproic acid in an effort to achieve haemostasis. At this point the patient had received twenty-two

units of packed red blood cells, twenty units of fresh frozen plasma, and seven units of platelets. As a last ditch effort to stop this life-threatening haemorrhage rFVIIa was injected intravenously with subsequent cessation of bleeding. She recovered slowly and was discharged without any thromboembolic complications six weeks later.

Literature Review and Discussion

There have been several case studies involving rFVIIa in surgical and trauma patients.^{2,5,6,7} These initial reports show promise for stopping haemorrhage in trauma and surgical patients. In many cases exsanguination was stopped shortly after infusion of rFVIIa and the administration of rFVIIa seemed to achieve haemostasis where other modalities had failed. Initially, there was considerable opposition for the use of rFVIIa in trauma and surgical patients due to the fear of thromboembolic sequelae. In several case reports, however, this fear has not been realised.

There are however several unanswered questions concerning the use of rFVIIa. First, the exact dosage required to achieve haemostasis is not known. The literature reveals that dosages of 40 to 120mcg/kg have been used from twice to twelve times and no clear consensus on how much rFVIIa should be administered has yet emerged. Second, in some cases other medications such as octreotide, tranexamic acid, and aminocaproic acid have been used and it is not known if rFVIIa alone is responsible for haemostasis. Third, under what clinical scenarios should rFVIIa be used? Could objective criteria, such as units of packed cells transfused or failure of other treatments, be constructed to show when rFVIIa is most effective? Finally, would the exorbitant cost of the drug (roughly \$AU13,000 per dose) prevent its widespread use? Prospective clinical trials should be undertaken to answer these questions and fully evaluate the efficacy of this promising medication.

In summary, consideration should be given to using all potential options in patients ensanguinating from a coagulopathy. In this case rFVIIa was successful.

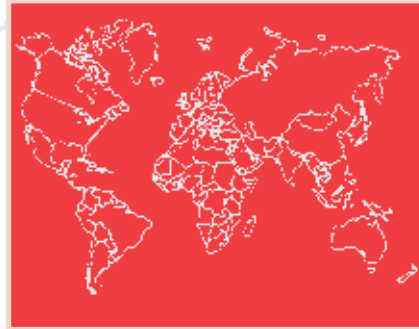

Bibliography

1. Sauer, A. et al. "Epidemiology of trauma deaths: a reassessment." *J Trauma* 1995; 38(2): 185-93.
2. Martinowitz, U. et al. "Recombinant activated factor VII for Adjunctive Hemorrhage Control in Trauma." *J Trauma* 2001; 51(3): 431-439.
3. Cotran: Robbins Pathologic Basis of Disease, 6th ed. 1999. W.B. Saunders Company. p. 117-124.
4. NovoSeven Product Monograph. November 2000. Rosen Bogtryk Publishing. p. 9-11.
5. Kenet, G. et al. "Treatment of traumatic bleeding with recombinant factor VIIa." *Lancet*. 1999;354:1897-1900
6. Vlot, A.J. et al. "Treatment of a severely bleeding patient without preexisting coagulopathy with activated recombinant factor VII." *Am J Med*. 2000; 108(5): 421-3.
7. White, B et al. "Successful use of recombinant FVIIa (NovoSeven) in the management of intractable post-surgical intra-abdominal haemorrhage." *Br J Haematol* 1999; 107(3): 677-8.

What's New in Trauma

**American College of Surgeons,
Committee on Trauma Verification
Review: Does it Really Make a Difference?
Ehrlich, P. et al, J Trauma 2002;
53:811-816**



**Vaccination Practices among North
American Trauma Surgeons in
Splenoectomy for trauma
Schatz, D., J Trauma 2002;
53:950-956**

Background:

Although not directly involved in designation per se, the American College of Surgeons (ACS) Committee on Trauma verification/consultation program in conjunction with Resources for Optimal Care of the Injured Patient has set the national standards for trauma care. Ehrlich and colleagues review the impact of a recent verification process on an academic health Center in West Virginia.

Methods:

Performance improvement data were generated monthly from the hospital trauma registry. Forty-seven clinical indicators were reviewed. Three study periods were defined for comparative purposes: PRE (January, June, October 1997), before verification/consultation; CON (April 1999-October 1999), after reorganization; and VER (November 1999-September 2000), from consultation to verification.

Results:

Statistically significant ($p < 0.05$) quantitative and qualitative changes were observed in numbers (percent) of patients reaching clinical criteria. These included prehospital, emergency department, and hospital-based trauma competencies. Trauma patient evaluation (including radiology) and disposition out of the emergency department (< 120 minutes) improved in each study section (PRE, 21%; CON, 48%; VER, 76%). Enhanced nursing documentation correlated with improved clinical care such as early acquisition of head computed axial tomographic scans in neurologic injured patients (PRE, 66%; CON, 97%; VER, 95%). Intensive care unit length of stay (< 7 days) decreased (PRE, 87%; VER, 97.8%). Other transformations included increase in institutional morale with recognition of trauma excellence within the hospital and resurgence of the trauma research programs (60 institutional review board-approved projects).

Conclusion:

The ACS verification/consultation program had a positive influence on this developing academic trauma program. Preparation for ACS verification/consultation resulted in significant improvements in patient care, enhancement of institutional pride, and commitment to care of the injured patient.

Background:

The purpose of this study was to examine trauma surgeons' practice patterns regarding immunization of splenic injury patients.

Methods:

Schatz analyzed data from surgeons responding to a survey sent to 557 adult trauma surgeons in the United States and Canada. The survey queried the timing and use of vaccinations in splenic injury patients.

Results:

Three hundred and four (54.6%) surgeons responded to the survey, with 43 no longer active. Of the 261 active surgeons, 99.2% immunize their splenectomized patients, whereas 15.7% immunize those who undergo splenorrhaphy and 8.4% immunize those managed nonoperatively. Vaccines are administered anywhere from the immediate postoperative period to as long as 6 weeks later. All but two responding surgeons provide the pneumococcal vaccine, 62.8% also advocate meningococcal vaccination, 72.4% add the Haemophilus influenzae vaccine, and 56.7% give all three. Thirteen of the responding surgeons reimplant splenic tissue, most frequently in the omentum, and in quantities varying from two slices to the entire spleen. Revaccination practices are extremely varied - ranging from nothing at all to annually - and seldom follow the Center for Disease Control and Prevention guidelines.

Conclusion:

With the exception of immunizing splenectomized patients against pneumococcal infection, little consensus exists amongst surgeons regarding the immunization of patients sustaining splenic injury.



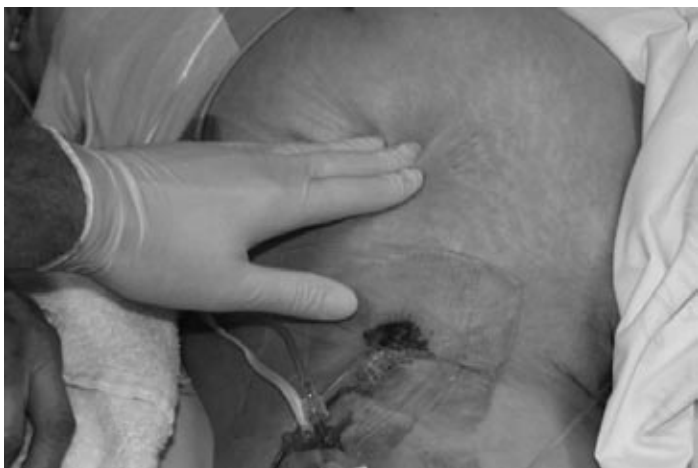

❄️ *Christmas 2002 Trauma Quiz* ❄️

Send your responses to Michael.sugreu@swsahs.nsw.gov.au. The winner will receive the trifactor of new Manual of Trauma Care, Trauma Rules and Manual of FAST. Entries close January 31st.

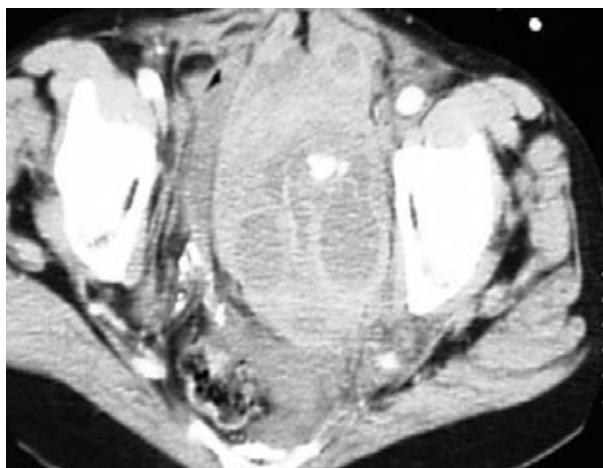
Question 1

How reliable is springing the pelvis in pelvic trauma in an unconscious patient?



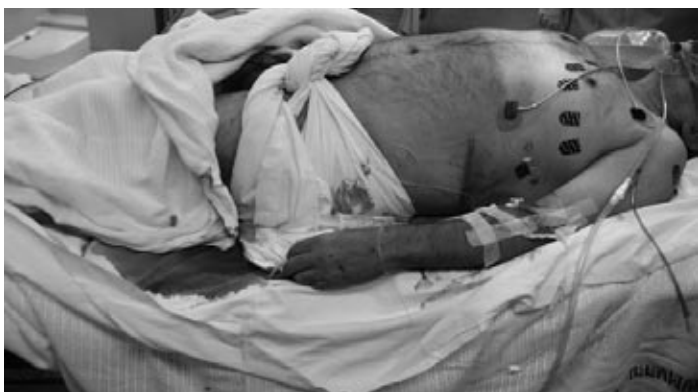Question 4

What does the CT show and what would you do next?



Question 2

Score out of 10 for non-invasive pelvic fixation: | 1 2 3 4 5 6 7 8 9 10

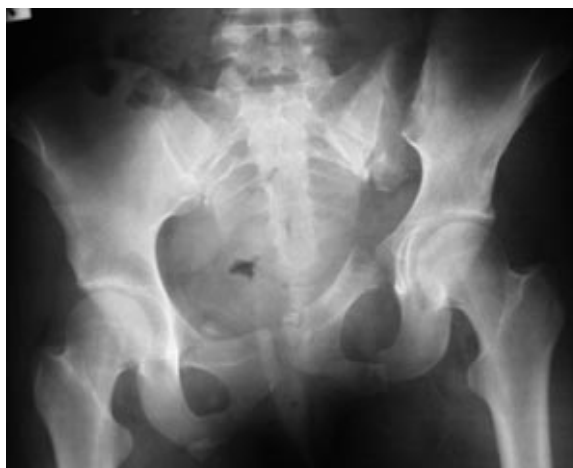
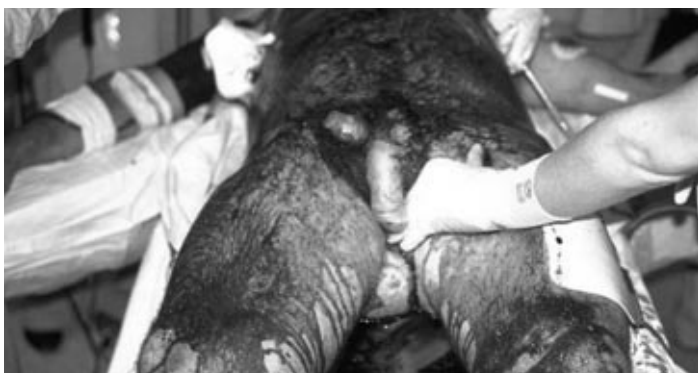
Question 5

What is the mechanism of injury?

Question 3

Patient is hypotensive with compound pelvic fracture - where should he go?



FOLLOW-UP TO

Case of the Month

Martin Heetveld, David Sloane Trauma Fellow

Remember our 23 year old male patient crushed by a bush buggy in a country paddock? The primary injury was to his chest with a lung contusion and on his second CXR a slightly abnormal mediastinum.

The questions were what would you do next?

Aortogram- While a CT could be performed given the abnormal CXR it is likely that there will be a haematoma in the mediastinum making it necessary to perform an aortogram anyway.

What potential injuries could the patient have?

Given the crush mechanism to the anterior chest, leading to his known bilateral pneumothorax and lower left rib fractures, this patient may potentially have blunt lung injury, splenic and or spinal injury. Splenic injury cannot be excluded on FAST. Liver injury is less likely, but must also be ruled out.

Should the patient be extubated?

Intubation was only necessary for helicopter transfer and the patient is ventilating well on arrival. Extubation should take place as soon as possible.

What actually happened to the patient?

ECG and measurement of the Troponin levels were normal. A CT abdomen showed no intra-abdominal injury. The cervical, thoracic and lumbar spine were imaged and no injury identified. The Cardiothoracic

surgical team was consulted for chest drain repositioning. Although the mediastinum on the chest X-ray was reported as normal, the cardiothoracic team ordered a screening CT of the mediastinum. The rationale behind this was that the mechanism of injury could still potentially cause aortic injury. An abnormal intimal flap at the beginning of the descending aorta was seen (Figure 1). An arch angiogram confirmed the intimal tear (Figure 2). The patient received an endoluminal aortic graft, effectively bypassing the injured area without complications.

Crush injury to the chest is less well known than deceleration trauma with chest compression as a mechanism for aortic injury. Compression of the aorta between the spine and the manubrium of the sternum due to crush can lead to aortic injury. This mechanism has been named the 'osseous pinch'.

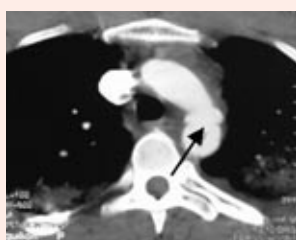

Figure 1

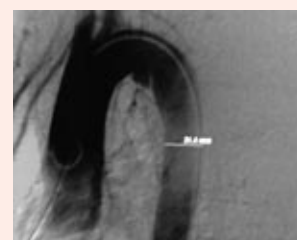


Figure 2

I Crass JR, Cohen AM, Motta AO, Tomashefski JF Jr, Wiesen EJ. A proposed new mechanism of traumatic aortic rupture: the osseous pinch. Radiology 1990 176(3):645-9.

Meetings

Definitive Surgical Trauma Care Course (DSTC)

Liverpool: 30st and 31st July 2003

Contact: Michael Sugrue or Charmaine Miranda (61 2) 9828 3928

Email: charmaine.miranda@swsahs.nsw.gov.au

For the Melbourne Course:

Contact: Peter Danne or Judy Forsyth (61 3) 9342 7232

Email: Judy.Forsyth@mh.org.au

SWAN XI

SWAN XI will be held on the 1st and 2nd of August, 2003, bringing to you nine world leaders in trauma care from overseas. Registration is limited, so get in early!

Contact: Thelma Allen

Email: thelma.allen@swsahs.nsw.gov.au

Phone: (61 2) 9828 3927

http://www.swsahs.nsw.gov.au/livtrauma

Remember if you are not a member of Australian Trauma Society - you could be!

Contact: (08) 8222 4408 phone (08) 8222 4970 fax

Email: bmitchel@mail.rah.sa.gov.au http://www.atsoc.com.au

World Congress on Abdominal Compartment Syndrome

December 6-8th Noosa Queensland 2004

Contact: Michael Sugrue or Charmaine Miranda (61 2) 9828 3928

Email: charmaine.miranda@swsahs.nsw.gov.au

BACKCHAT

The Institute of Trauma and Injury Management (ITIM) of NSW has to be congratulated for their progress in revitalizing imperatives in Trauma Care in NSW. The team is led by Professor Danny Cass and assisted by Trish McDougall, Andrea Delprado and Margaret Perrett.

Contact details:

NSW Institute of Trauma and Injury Management

P O Box 6314, North Ryde NSW 2113

Level 3, 51 Wicks Road, North Ryde

Phone: (02) 9887 5726

Fax (02) 9887 5646

Email: margaret.perrett@doh.health.nsw.gov.au

Liverpool Hospital has just produced a 300 page colour trauma manual. This is available from the Trauma Department at a cost of \$30 including posting. Handbook

of Trauma Care D'Amours SK, Sugrue M, Russell R, Nocera N ISBN 1740790278 2002

We welcome Dr Zolt Balog from USA as our new David Sloane Trauma Fellow following on the footsteps of Dr Martin Heetveld who has spent 12 months in this position, and now returns to Amsterdam.

Congratulations to the following winners in their categories for best papers at the recent very successful Southern Trauma Symposium and ATS meeting in Melbourne:

• Owen Williamson, The Alfred Hospital – Medical Digital imaging of ankle fractures: Can an accurate management decision be made via email?

• Erica Caldwell, Liverpool Hospital – Nursing Injury admissions to a MTS as a result of intentional self harm.

• Soundappan Soundappan, Children's Hospital Westmead – Medical FAST in children with blunt torso trauma.

• Craig Frazer and Liz Parris, The Alfred Hospital – Paramedic

A 12 month orthotic review of halo-thoracic orthosis in the treatment of cervical spine injuries: Device performance, patient perceptions.

We wish our two departing honorary fellowships Dr Robert Russell and Mr Suraj Nagori all the best in their respective careers.



Gelofusine[®]

Modified Fluid Gelatin



The Premium Gelatin Colloid

PBS General Benefit: 500ml x 3 bottles

B | BRAUN
HOSPITAL CARE

The Trauma Department would like to acknowledge the support of
B.Braun Australia Pty Ltd
producers of Gelofusine[®] in the publication of the Trauma Grapevine

©1996 Trauma Department Liverpool Letters to Dr Michael Sugrue
Trauma Department, Liverpool Hospital,
Elizabeth Street NSW 2170 Fax 9828 3922

www.swsahs.nsw.gov/livtrauma Email: michael.sugrue@swsahs.nsw.gov.au

The Trauma Grapevine is owned, published, copyrighted © 2001 It is sponsored by B Braun All rights reserved.
Editorial Offices: Trauma Department Liverpool Hospital Locked bag 7103 Liverpool BC 1871 Australia Phone: (61) 2 98283927 FAX: (61) 2 98283926
Editorial Board Scott D'Amours Trauma Surgeon Liverpool Hospital, Tim Hodgetts Professor Emergency Medicine Birmingham, Kenth Johansson, General and Trauma Surgeon Vastervik Sweden, Karel Kolkman, Trauma Surgeon Holland, Martin Jones Rural Surgeon Nowra NSW, Kathy Martin Trauma Coordinator Philadelphia USA Michael Sugrue Trauma Surgeon Liverpool, Don Trunkey Trauma Surgeon Oregon USA. ISSN 1329-2846